

### Patient position and method:

Patient in a lateral position with the side to be blocked uppermost. The lower leg is stretched, the leg that is to be blocked is flexed in hip and knee-joint.

### Guiding structures:

Greater trochanter, superior posterior iliac spine.

Draw a line between the sup. post. iliac spine and the greater trochanter, from its midpoint a perpendicular line is drawn caudomedially. The needle insertion point is 4 – 5 cm from the first line. A confirming line can be drawn from the trochanter to the sacral hiatus, the insertion point is where the last two lines cross each other. The stimulation needle is advanced perpendicularly to the skin. After 5 – 10 cm, contractions of the dorsiflexors of the foot (common peroneal nerve) or of the plantar flexors of the foot (tibial nerve) at 0.3 mA/0.1 ms indicate the correct position of the needle in the immediate vicinity of the sciatic nerve.

### Comments on the technique:

- Occasional vascular puncture (inferior gluteal artery)
- Direct stimulation of the major gluteal muscle must not be mistaken for the sciatic nerve stimulation response (inject local anaesthetic only at a stimulus response in the lower leg/foot)
- Local LA infiltration recommended

### Indications:

- All leg surgery when combined with a lumbar plexus block
- Pain therapy (knee joint on the flexor side, lower leg)
- Sympathicolysis

### Special contraindications:

None

### Relative contraindications:

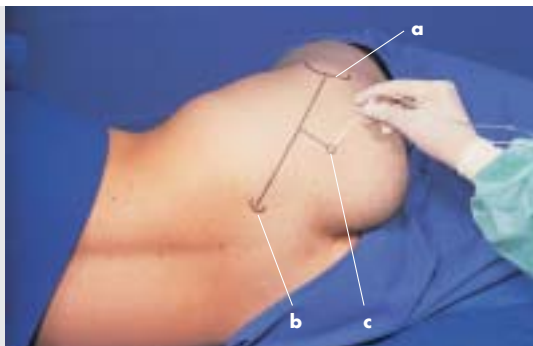
Coagulation disorder (Risk of puncturing inferior gluteal artery)

### Local anaesthetics:

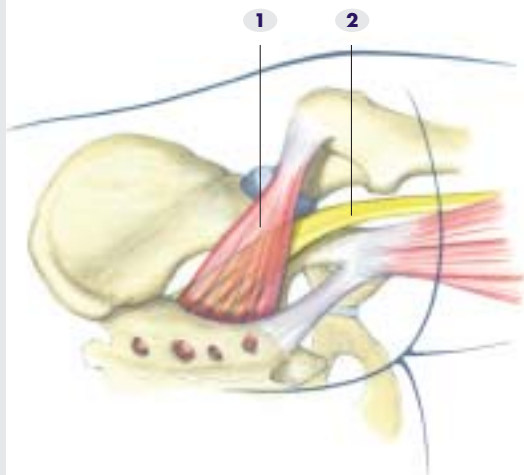
30 – 40 ml lidocaine 1% or mepivacaine 1% or  
30 ml ropivacaine 0.75%

**Needle:** E. g. 20 G 10 or 15 cm long, insulated unipolar needle with 30° or 15° bevel

- a** greater trochanter
- b** superior posterior iliac spine
- c** site of insertion:  
direction of needle  
perpendicular to  
the skin, 5 – 10 cm  
deep



- 1** piriformis m.
- 2** sciatic n.



### Patient position and method:

The patient is supine with the leg to be blocked flexed at hip and knee approx. 90° and held by an assistant.

### Guiding structures:

Greater trochanter, ischial tuberosity.

Draw a line between the greater trochanter and the ischial tuberosity and mark its midpoint. This point marks the site for needle insertion. The stimulation needle is advanced perpendicular to the skin surface in a cranial direction. After 5 – 10 cm, contractions of the dorsiflexors of the foot (peroneal n.) or of the plantar flexors (tibial n.) at 0.3 mA/0.1 ms indicate the correct position of the needle.

### Comments on the technique:

Advantage: The patient can remain supine. The technique is easy to learn. The leg can also be placed in a leg support. A continuous technique can be used.

### Indications:

- Most types of surgery on the leg when used in combination with a lumbar plexus block
- Pain therapy
- Sympathicolysis

### Special contraindications:

None

### Local anaesthetics:

#### Initial:

30 ml lidocaine 1% or mepivacaine 1% or  
20 – 30 ml ropivacaine 0.75%

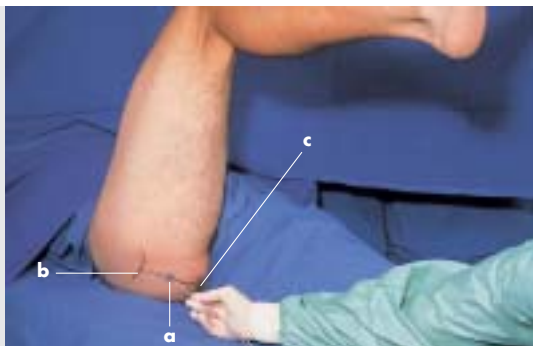
#### Continuous:

6 ml (5 – 15 ml) ropivacaine 0.2 – 0.375%, max. 37.5 mg/h or bolus (alternatively): 20 ml ropivacaine 0.2 – 0.375% (approx. every 6 hours)

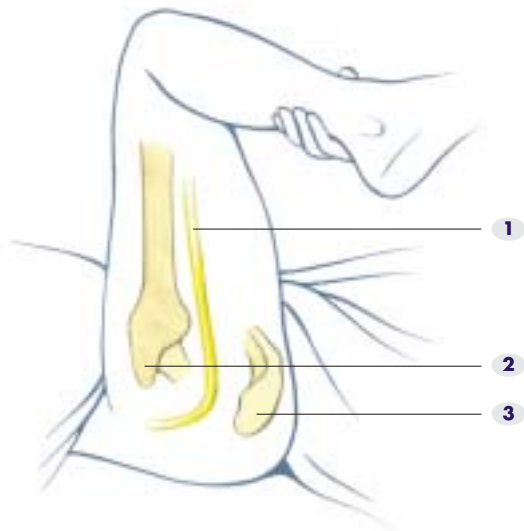
**Needles:** 10 cm, 20 G, 30° or 15° bevel unipolar needle

Continuous: E. g. 19.5 G, 10 cm bevel, Plexolong set® (Pajunk co.), Contiplex® (B. Braun)  
The catheter is advanced 4 – 5 cm beyond the needle tip in a cranial direction

- a** site of insertion:  
midpoint of line  
between the  
greater trochanter  
and the ischial  
tuberosity
- b** greater trochanter
- c** ischial tuberosity



- 1** sciatic n.
- 2** greater trochanter
- 3** ischial tuberosity



### Patient position and method:

Patient supine with the leg in a neutral position.

### Guiding structures:

Superior anterior iliac spine, middle of the symphysis, greater trochanter, the intermuscular space between the sartorius m. and the rectus femoris m. The connecting line between the anterior iliac spine and the middle of the symphysis is divided into three equal segments. Draw a line parallel to this line through the middle section of the greater trochanter. Then draw a perpendicular line from the junction of the medial and middle segments in a caudal direction. The point where the lines cross each other marks the needle insertion site. Palpate the intermuscular space between the sartorius m. and the rectus femoris m. in this region. Advance the needle at a 60° angle approx. 8 – max. 15 cm in a cranial direction. Avoid bone contact. A motor stimulus response in the foot (dorsi- or plantar flexion at 0.3 mA/0.1 ms) indicates that the needle tip is in the immediate vicinity of the sciatic nerve.

### Comments on the technique:

The palpation of the space between the sartorius and rectus femoris muscles is very important, because the femoral vessels are displaced medially and the distance to the injection site is shortened as a result of the vertical pressure ("two-finger grasp").

### Indications:

- Most surgery on the leg when combined with a lumbar plexus block
- Pain therapy (also as a continuous technique)
- Sympathicolysis

### Special contraindications:

None

### Local anaesthetics:

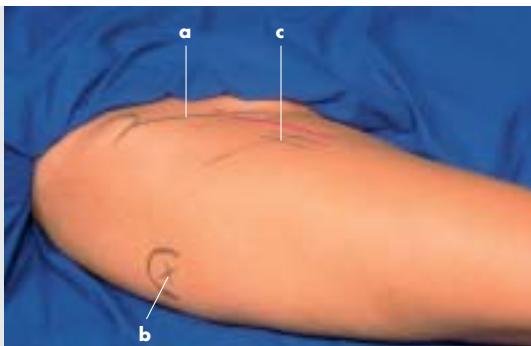
**Initial:** 30 – 40 ml lidocaine 1% or mepivacaine 1% or 20 – 30 ml ropivacaine 0.75%

**Continuous:** 6 ml (5 – 15 ml) ropivacaine 0.2 – 0.375%, max. 37.5 mg/h or bolus (alternatively): 20 ml ropivacaine 0.2 – 0.375% (approx. every 6 hours)

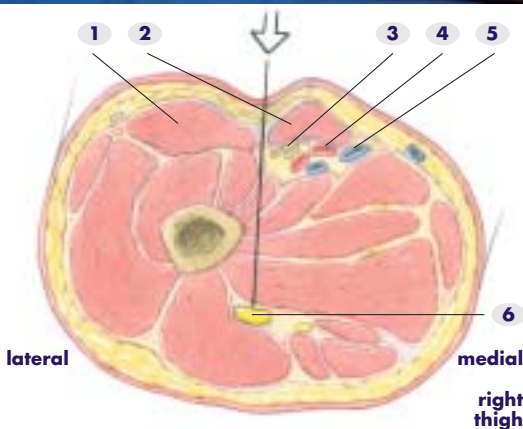
**Needles:** 20 G, 15 cm, 30° or 15° bevel, insulated unipolar needle

Continuous: E. g. 19.5 G, 15 cm, facet tip, Plexolong set® (Pajunk co.) or Contiplex® set (B. Braun) 20 G catheter. The catheter is advanced approx. 4 cm beyond the tip of the cannula

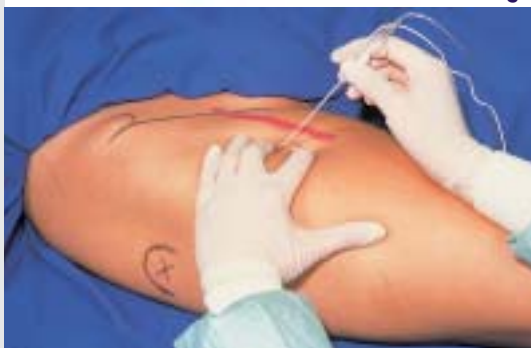- a** the connecting line between the sup. ant. iliac spine and the middle of the symphysis
- b** greater trochanter
- c** needle insertion site



- 1** rectus femoris m.
- 2** sartorius m.
- 3** femoral n.
- 4** femoral a.
- 5** femoral v.
- 6** sciatic n.



Direction of needle insertion  
 Note:  
 "two-finger grasp"  
 into the intermuscular space, sciatic nerve at a depth of 8 – 15 cm.



### Patient position:

Patient supine. The leg lies in neutral position. A small pad or pillow is placed under the foreleg.

### Guiding structures:

Greater trochanter, femur shaft.

A line is drawn distally from the prominent part of the greater trochanter parallel to the femur. The injection site is approx. 3 cm below this line at 5 cm distal to the greater trochanter. The needle enters at the level of the dorsal border of the femur and the needle is directed dorsally (approx. 30°) and cranially (approx. 30 – 45°). The sciatic nerve is reached after 8 – 10 cm.

### Comments on the technique:

Muscular contractions in the posterior thigh are frequent. The correct position of the needle tip in the vicinity of the nerve is confirmed by a motor response in the foot (dorsiflexion or plantar flexion) with a pulse amplitude of 0.3 mA and a pulse width of 0.1 ms. The peroneal nerve is in front of the tibial nerve. Dorsiflexion of the foot is therefore usually the initial motor response. If no motor response is produced, the needle should be withdrawn and its direction should be corrected anteriorly when it is advanced again.

### Indications:

- All operations on the leg in combination with a lumbar plexus block
- Pain therapy
- Sympathicolysis

### Special contraindications:

None

### Local anaesthetics:

#### Initial:

30 ml lidocaine 1% or mepivacaine 1% or 20 – 30 ml ropivacaine 0.75%

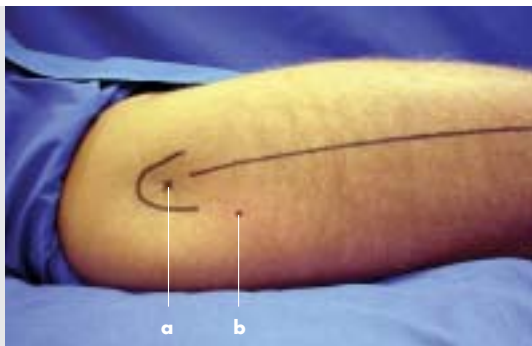
#### Continuous:

6 ml (5 – 15 ml) ropivacaine 0.2 – 0.375%, max. 37.5 mg/h or bolus (alternatively): 20 ml ropivacaine 0.2 – 0.375% (approx. every 6 hours)

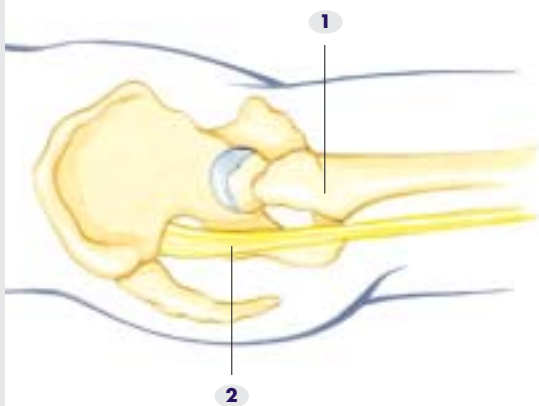
**Needles:** 20 G, 10 cm, 30° or 15° unipolar needle

Continuous: E. g. 19.5 G, 10 cm, faceted tip, Plexolong set® (Pajunk co.). The catheter is advanced 4 – 5 cm beyond the needle tip in a cranial direction.

- a** greater trochanter with a line parallel to the femur
- b** needle insertion site 5 cm distal to the greater trochanter and 3 cm below line a (just behind the femur)



- 1** greater trochanter
- 2** sciatic n.



Direction of needle:  
approx. 30°  
dorsally and  
cranially

